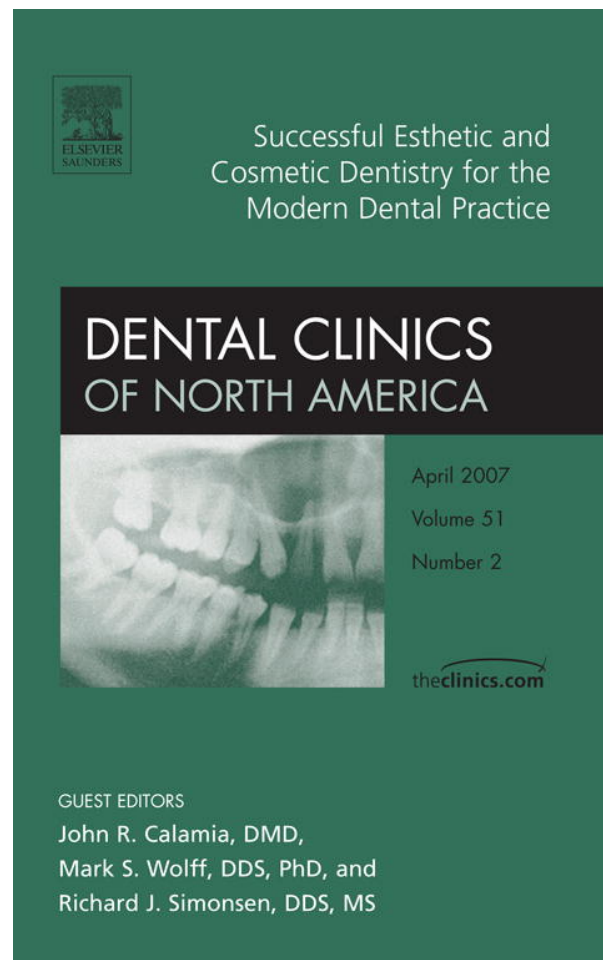


Provided for non-commercial research and educational use only.
Not for reproduction or distribution or commercial use.



This article was originally published in a journal published by Elsevier, and the attached copy is provided by Elsevier for the author's benefit and for the benefit of the author's institution, for non-commercial research and educational use including without limitation use in instruction at your institution, sending it to specific colleagues that you know, and providing a copy to your institution's administrator.

All other uses, reproduction and distribution, including without limitation commercial reprints, selling or licensing copies or access, or posting on open internet sites, your personal or institution's website or repository, are prohibited. For exceptions, permission may be sought for such use through Elsevier's permissions site at:

<http://www.elsevier.com/locate/permissionusematerial>

Aesthetic Anterior Composite Restorations: A Guide to Direct Placement

Brian P. LeSage, DDS^{a,b,c,*}

^a*Beverly Hills Institute of Dental Esthetics, CA, USA*

^b*UCLA Aesthetic Continuum, CA, USA*

^c*Department of Restorative Dentistry, UCLA Dental School, CA, USA*

Mastering anterior direct composite restorations is a necessity for the contemporary clinician who appreciates and understands the art and science of cosmetic dentistry. In the esthetic zone, composite bonding procedures are considered the most conservative and least invasive technique to return missing, diseased, and unsightly tooth structure to enhanced color, form, and function. The attractiveness and popularity of composites are easy to explain because these restorations have excellent esthetic potential, very good to excellent prognosis, and a reasonable fee [1,2].

Composites are the most versatile restorative material available to the dental professional, especially for the esthetic-conscious patients. The restorative dentist can use this versatile material in a mirage of indications and techniques. It is used as a direct and indirect restorative material on anterior and posterior teeth, orthodontics attachments and bracket cement, indirect restoration cements, correction of erosive and abfraction lesions, bases, liners, core build-ups and post and cores, mock-up for anterior esthetic or posterior occlusal trial therapy, splinting, provisionalization, gingival stabilization, and so forth.

For composite restorations to mimic natural tooth structure, the clinician must have a comprehensive understanding of the material science and techniques involved in direct bonding procedures. Material science can be broken down to include types of composites, tints, opaquers, adhesive systems, and armamentarium. The necessary techniques involve an understanding of color, adhesive principles, layering to create polychromicity, incisal effects and perfect imperfections, and finishing and polishing.

* 436 North Roxbury Drive, Suite 100, Beverly Hills, CA 90210.

E-mail address: brian@cosmetic-dentistry.com

Composite materials

Composition

A composite is a multiphase substance formed from a combination of materials that differ in composition or form, remain bonded together, and retain their identities and properties [1]. They have four main components: (1) resin (organic polymer matrix); (2) filler (inorganic) particles; (3) coupling agent (silane); and (4) the initiator-accelerator of polymerization.

Resin matrix

Manufacturers prefer Bis-GMA resins because they have an aromatic structure that increases stiffness and compressive strength and lowers water absorption [2]. Bis-GMA 2,2-bis [4(2-hydroxy-3 methacryloyloxypropyloxy)-phenyl] propane is the most popular dimethacrylate resin, but to accommodate better filler load triethylene glycol dimethacrylate or urethane dimethacrylate is added [3].

Fillers

Filler (inorganic) particles provide dimensional stability to the soft resin matrix [2]. The filler particles used in composites vary in size from less than 0.04 μ to over 100 μ . Common fillers are crystalline quartz; colloidal and pyrolytic silica; and such glasses as lithium, barium, or strontium silicate.

Coupling agent

Silane helps form a good bond between the resin matrix and filler particles during setting. The silane contains functional groups (eg, methoxy) that hydrolyze and react with the inorganic filler, and unsaturated organic groups that react with the resin matrix during polymerization [3].

Initiators and accelerators of polymerization

Composites contain initiators and accelerators that allow for light-, self-, and dual-cure modes. For visible light activation, camphoroquinones (0.03%–0.09%) start the free radical reaction using blue light in the 468 nm \pm 20 nm range [2]. In the esthetic zone, light-cured composites are the material of choice because color matching and color stability are the most predictable.

For chemical-cured composites, aromatic tertiary amine (2%) initiates the free radical reaction when the paste and catalyst are mixed. Tertiary amines (and HEMA found in many adhesive systems) have been found to cause color change in composites on polymerization [4].

Classification and application

Historically, composites have been classified by particle size, shape, and distribution of fillers [5,6]. In the 1980s and 1990s, composite technology developed and became refined into two classifications: microhybrids and microfills. At the new millennium, nanotechnology introduced a new class of composite: the nanofillers. The three classifications of composites have their very distinct indications, advantages, and disadvantages (Table 1).

An ideal composite consists of the following four qualities: (1) mirror natural tooth structure in color and translucency; (2) strength to withstand function in stress-bearing areas for the long-term; (3) seamless or undetectable margins from restoration to tooth for the long-term; and (4) achieve the appropriate contour and polish (luster and finish) and maintain it for the long-term [7].

Microhybrid


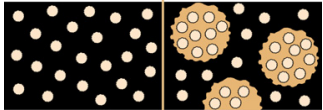

Microhybrids contain a distribution of two or more irregular-shaped, but rather uniform diameter, “glass” or quartz particles of 0.2 to 3 μm plus 5% to 15% 0.04- μm microfine particles. This distribution of fillers makes the microhybrid 60% to 70% filled by volume, which translates roughly into 77% to 84% by weight [2,3,8] (Table 2).

The particle sizes and distribution and percent filled by weight lead to the following advantages for the microhybrid composite: strength; lower polymerization shrinkage (0.6%–1.4%); lower coefficient of thermal expansion; lower values of water sorption; higher flexural strength; and higher Knoop hardness [2,3,8]. Their disadvantage is maintaining a polish for the long-term.

Table 1
Indications, advantages, and disadvantages of the three major categories of composite resins

Classification	Indications	Advantages	Disadvantages
MicroHybrid	Layer the desired shade deep within the restoration to mimic dentin and enamel morphology Provide strength in any functional area	Strength: less likely to chip in high-strength area Refractory properties: opacity similar to enamel and dentin	Polishability: not long-term
MicroFill	Replace enamel in color and translucency Polish ability Wear resistance and surface texture	Polishability: high shine for the long-term Wear: resistance better than microhybrids Refractory properties: translucency similar to enamel	Lacks strength for some functional areas Can be too translucent
NanoFiller	All anterior and posterior restorative applications??	Potential advantages of MicroHybrid and MicroFill	No in vivo long-term studies

Table 2
Filler sizes in the three major categories of composite resins

Classification of composite	Size of filler particles (μm)	Volume of inorganic filler (%)	Filled by weight (%)	Diagram
MicroHybrid	0.2–3 plus 0.04	60–70	77–84	
MicroFill	0.02–0.04	32–50	50–70	
NanoFiller	0.01–0.04	60–72	79–84	

From an esthetic standpoint, microhybrids have more opacity and are excellent in replacing dentin. Microhybrids with smaller average particle sizes are excellent in replacing enamel and can be good to excellent in holding their polish over time. Examples of contemporary microhybrids include Herculite and Point 4 (Kerr/Sybron, Orange, California), Filtek Z250 (3M ESPE, St. Paul, Minnesota), and Vit~1~escence (Ultradent Products, Inc., South Jordan, Utah).

Microfills

Microfills contain colloidal silica fillers of 0.04- μm particle size and a filler loading of 32% to 50% by volume, which equates to 50% to 70% by weight [3,8] (see Table 2).

Because microfills are less highly filled, they have higher polymerization shrinkage, coefficient of thermal expansion, and water sorption compared with microhybrid composites. They demonstrate excellent polish and wear characteristics. Their disadvantage is strength and in some clinical situations being too translucent.

From an esthetic standpoint, microfills are superior to microhybrids. Microfills are excellent in replacing enamel, creating translucent zones, and having appropriate anatomy and high polish for the long-term. Examples of contemporary microfills include Filtek A110 (3M ESPE, St. Paul, Minnesota), Renamel (Cosmodent, Chicago, Illinois), and Matrixx Anterior Microfill (Discus Dental, Culver City, California).

Nanofillers

Two nanofillers are the aggregated zirconia-silica cluster filler (3M) with an average cluster particle size of 0.6 to 1.4 μm with primary particle size of 5 to 20 nm and a nonagglomerated-nonaggregated 20-nm silica filler [9]; and the Kerr prepolymerized filler (30–50 μm ; barium glass, 0.4 μm ; and silica nanoparticles, 0.02 μm). Nanofillers contain zirconia-silica nanocluster fillers of 30 to 50 μm (0.02 μm) plus submicron 0.01 to 0.02 μm silica particles. Nanofillers exhibit filler loading of 60% to 72% by volume, which equates to 79% to 84% by weight [9] (see Table 2). Examples of contemporary nanofillers include Premise (Kerr/Sybron, Orange, California), Aelite Aesthetic Enamel (Bisco, Schaumburg, Illinois), and Filtek Supreme Plus Universal Restorative (3M, St. Paul, Minnesota).

Being relatively new, nanofillers have few long-term in vivo studies, which is their disadvantage. Some shorter-term studies exist, and empirically this classification of composite has the potential to exhibit the advantages and limit the disadvantages of the other two composite classes. Because of their higher volume percent loading they exhibit lower shrinkage and associated less pull on margins, adhesives, and interproximal contact issues. More studies over a longer period of time are very much needed, however, to support such an opinion.

Adhesive systems and techniques

The success of composite restorations is directly related to the success of the adhesive system and technique used. Adhesive dentistry when applied correctly can prevent the dislodgement of composite restorations, prevent sensitivity issues, prevent microgap formation or microleakage leading to recurrent decay, and so forth. In article by Dr. Perdigao, a complete and comprehensive understanding of adhesives can be gained.

Tints

A tint is a color that is mixed with white. The tinted range of any one color can run from the pure color at its maximum intensity through to white [10]. For the restorative dentist, a tint's primary indication is to match natural tooth structure in polychromicity and maverick colors. It can also be used to help mask out the tooth-restoration interface. The effect on color is to lower the value. Tints are very intense colors and need to be used judiciously (Table 3).

Opaquers

Opacity is the opposite of transparency, and describes the degree to which light is prevented from passing through the color. It sometimes is described as "covering power," and is the color's ability to cover an underlying color, preventing any trace of the latter showing through [10].

The primary indication for an opaquer is to block out any size, shape, and degree of darkness within a tooth using only a thin layer of material. If the restorative dentist can create a stump shade that is uniform in polychromatic color, the final restoration need only reproduce the value and translucency of enamel. Opaquers can also help to block out the tooth-restorative interface and block out excessive translucency in CL III and IV restorations. Their effect on color is to raise value (see Table 3).

Table 3
Overview of tints and opaquers

	Indications
Tints	Match natural tooth structure in polychromicity and maverick colors Help mask out tooth-restorative interface Lower the value
Opaquers	Raise the value Block dark tooth color in thin layer Help mask out tooth-restorative interface Block excessive translucency in CL III and IV restorations

Layering techniques

Overview

When considering the direct anterior restoration in composite, one needs only to borrow from nature. If one studies and understands natural tooth structure in color, form, and function, then composite mirroring becomes the objective. Composite mirroring is the natural replacement of teeth with minimal or no additional removal of the intact, health dentition to normal form and function with tooth-colored material. With this approach, the restorative dentist must indulge the optical, anatomic, and functional characteristics of natural teeth.

In composite mirroring, the restorative dentist chooses an enamel and dentin replacement material that emulates the missing tooth structure in optical properties and strength. Clinically, this can be oversimplified by using a microhybrid in any area requiring strength or dentin replacement and a microfill for polishability and enamel replacement and effects (Fig. 1, Table 4). Figs. 2–5 shows a more in-depth breakdown of the composite mirroring system. Nanofillers, with more clinical data, may eventually eliminate the need for both systems.

When used properly, the composite mirroring system of layering is crucial in creating life-like restorations in strength and esthetics including polychromicity and incisal effects. The layering of composite material can be simple, involving one or two shades, or advanced, mimicking the artistic skills of the ceramic technician. When describing the four layering technique, trying to simplify or categorize which layering technique is




Fig. 1. Simplified, generalized overview of the composite mirroring system. Brown area using microhybrid for the stress-bearing zone (strength for the long-term), and beige area using a microfill for esthetics (polishability for the long-term). (Courtesy of Brian LeSage, DDS, Beverly Hills, CA.)

Table 4
Overview of tooth structure replacement and classification of composite resins

Tooth structure being replaced	Microhybrid	Microfill
Enamel: stress-bearing area	++++	+ (need support of tooth)
Enamel: pure esthetic area	++~+++	++++
Dentin: pure esthetic area (ie, CL III, V)	+++~++++	+++~++++ (higher chroma needed)
Dentin: stress-bearing area (ie, CL IV)	++++	+ (need support of MicroHybrid)

Abbreviations: ~, not indicated; +, least indicated; +++++, highly indicated.

best, the clinician needs to consider the patient's financial commitment and the esthetic wants of the patient. Visualization, being able to see and believe in creating the end point, is critical. The purpose of composite layering is to establish the dentin layer and dentinal lobes in a tooth and create the wonderful nuances of enamel and enamel effects that transform into incisal translucency and incisal halo effects [7,11–16,17–21].

Shade selection technique

The shade selection technique is as follows [18,22–26]:

1. Pumice tooth lightly to remove any stains, debris, pellicle, and so forth, but not so much as to influence the tooth's natural luster and finish. Otherwise, this could affect the predictability of shade matching (Fig. 6A).
2. The dentin shade is best obtained from the gingival third of the tooth where the enamel is the thinnest (Fig. 6B) or from the canines where




Fig. 2. Simple layering technique. Brown area demonstrating the use of one shaded material, and the hashed zone an optional second shaded material of different opacities and the same or different chroma range. (Courtesy of Brian LeSage, DDS, Beverly Hills, CA.)




Fig. 3. Less simple layering technique. Same as simple layering technique with the addition of a translucent zone internally to help distinguish the dentinal lobes and create incisal effects. (Courtesy of Brian LeSage, DDS, Beverly Hills, CA.)

the chroma is the greatest. Clinically, this is done by placing a small thin convenience form of the anticipated shade in the gingival third and light curing. This must be done before the teeth dehydrate. It should be noted that microhybrids generally get darker on light curing, and microfills get lighter when light cured.

3. The enamel shade is conveniently obtained in the middle third of the tooth, where the enamel is the thickest (Fig. 6C).
4. The incisal or translucent shade is observed in the incisal third of the tooth, where the enamel is the thickest and there is little dentin opacity. In most anterior teeth the translucent zone is not limited to the incisal edge but carries into the transitional line angle zones (Fig. 6D).
5. Color mapping by the clinician doing the esthetic composite restoration aids the clinician because these procedures can be lengthy and often the operator's eyes fatigue physically and mentally. The color map is a picture or prescription to be used as a guide throughout the fabrication of the direct restoration (Fig. 6E).
6. Practice mock-up using the selected shades can be done quickly without good adhesive technique to act as a shade evaluation guide and subsequently to fabricate a putty matrix. Once one is satisfied with the color based on the mock-up, the clinician turns their attention to contour. Modify the mock-up to obtain the correct outline form, embrasure form, incisal edge, and incisal plane contour to the facial-incisal line angle (do not spend time getting the facial surface ideal at this point). At the same time, get the centric stops and anterior disclusion that is needed for longevity. Once the occlusion and contours

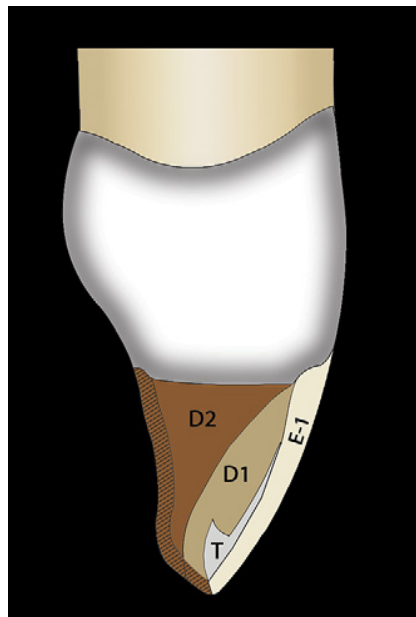


Fig. 4. 3-D Advanced Layering Technique. Brown area demonstrating the use of TWO opacious shaded materials varying in chroma (D2-Higher Chroma Dentin opacious shade, D1-Lower Chroma Dentin opacious shade) and a translucent zone (T) internally to help distinguish the dentinal lobes and additionally an outer layer of enamel material (E) of the same or different chroma range. Lingual hashed enamel layer can be the E shade or the D2 shade. (Courtesy of Brian LeSage, DDS, Beverly Hills, CA.)

are correct, use a stiff VPS material, such as Aquasil Ultra Rigid (Dentsply/Caulk), Affinity (Clinician's Choice), Imprint II (3M ESPE), and Exaimplant (GC), to fabricate a putty matrix that captures the entire lingual contour completely to the facial-incisal line angle [27] (Fig. 6F, G, and H).

Simple layering technique

This technique should be considered for the patient who has minimal esthetic concerns, but when all decisions are based on economics. One or two shaded materials (with different opacities and the same or different chroma range) suffice (see Fig. 2).

Less simple layering technique

This technique should be considered for the patient who has moderate esthetic concerns, but when decisions are based primarily on economics. It entails one or two shaded materials (with different opacities and the same or different chroma range) and another layer using incisal shaded material (Fig. 3).

Three-dimensional advanced layering technique

This technique should be considered for the patient who has a moderate to extensive understanding of esthetics and when finances play minimally

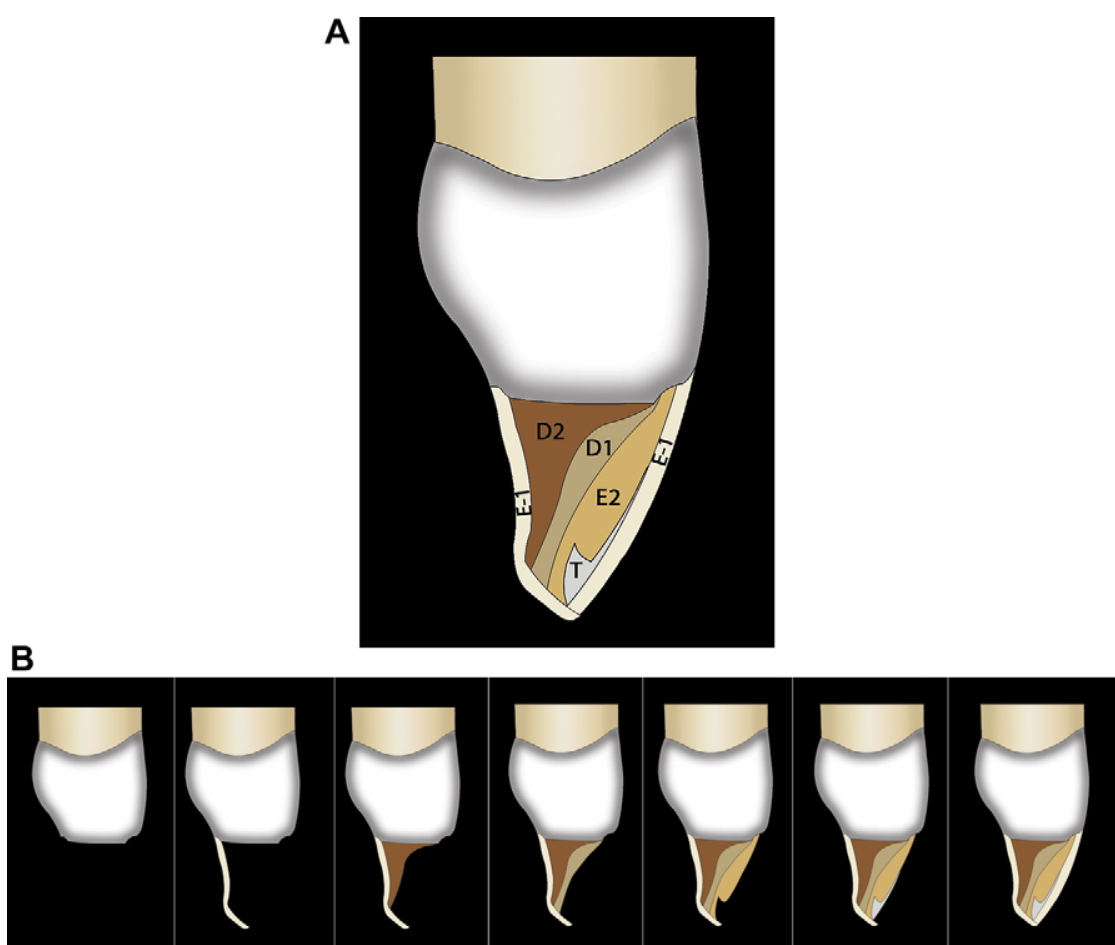


Fig. 5. (A) 3-D Characterized Layering Technique. Same as 3-D Advanced Layering technique with the lingual enamel layer being a distinct (E) layer. And the addition of a second facial enamel layer of differing chroma range to internally give depth to the dentinal lobes and create incisal effects mirroring mother nature. Not shown is the tint layer placed internally creating maverick colors and effects. (B) Sequential application and layering starting from the lingual and extending to the facial with multiple dentin and enamel shades, and a translucent shade. (Courtesy of Brian LeSage, DDS, Beverly Hills, CA.)

into their decision-making process. Two shaded materials with different chromas are used to replace dentin, with an enamel layer for enamel effects and another layer using incisal shaded material (Fig. 4).

Three-dimensional characterized layering techniques

This technique should be considered for the patient who has a very high esthetic intelligence quotient and is very esthetically demanding, and when finances are not part of their decision-making process. Two shaded materials with different chromas are used to replace dentin, two shaded materials with different chromas are used for the enamel layer for enamel effects, and another layer uses incisal shaded material. A characterization layer is placed between the incisal and enamel layers or the two enamel layers depending on the intensity of the effect desired (Fig. 5). Tints are placed internally to

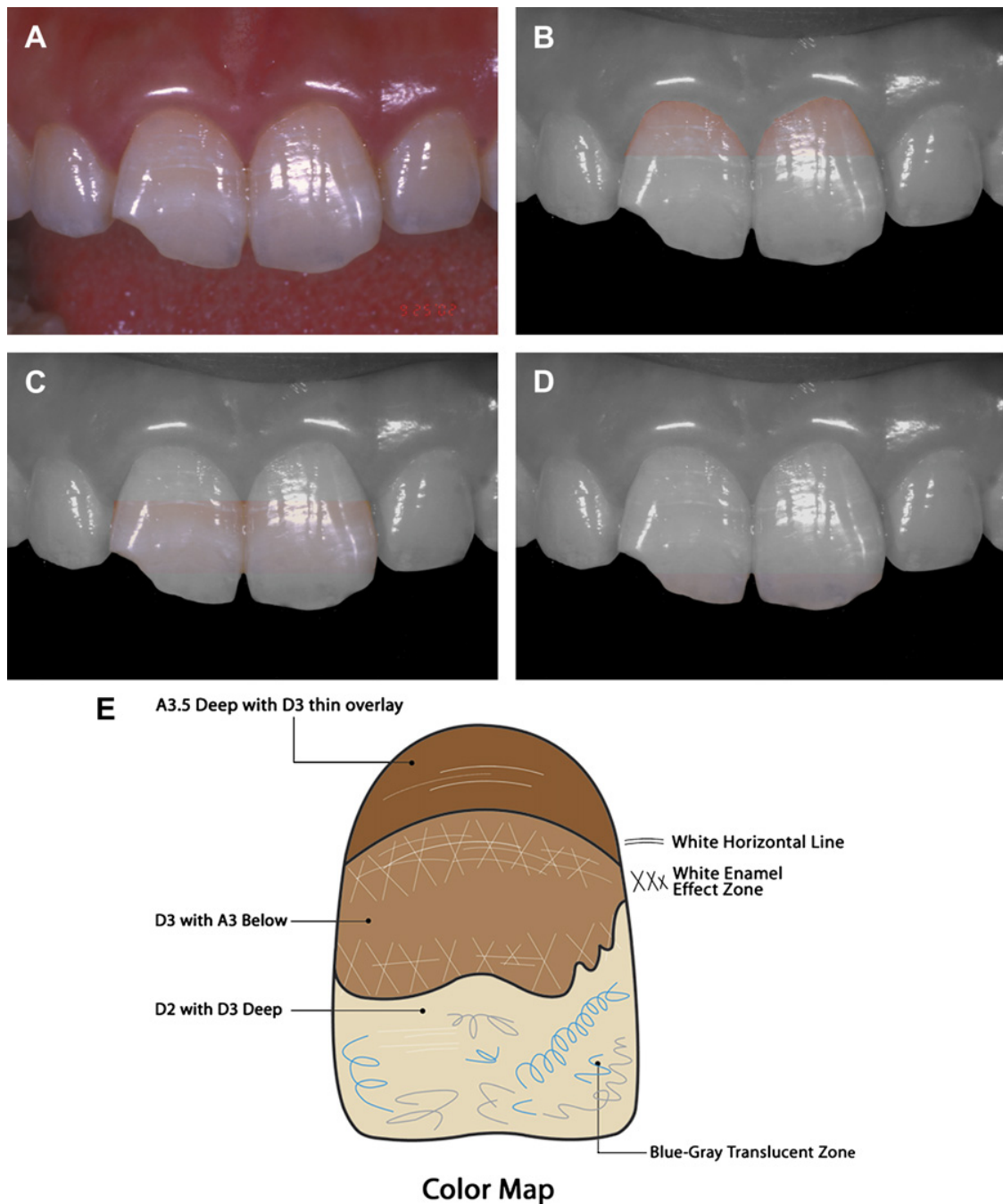


Fig. 6. Shade Selection Technique. (A) Before picture at 1:1 showing worn and chipped areas after lightly pumicing. (B) Highlighted gingival 1/3 for dentin shade selection. (C) Highlighted middle 1/3 for enamel shade selection. (D) Highlighted incisal 1/3 for translucent shade selection. (E) Color mapping to aid in shade predictability. (F) Mock-up used for preliminary shade determination and 3-D spatial relations to fabricate putty matrix. (G) Putty Matrix trimmed properly to the facial incisal line angle. Note bevel and star burst bevel. (H) Final restoration appearing seamless and mirroring mother nature. (Courtesy of Brian LeSage, DDS, Beverly Hills, CA.)

mirror the unique characterizations of the natural tooth, such as subsurface staining or demarcations of any color, shape, or size.

The outer layer is unique and preplanned in this technique. If the desired outcome is a brighter (higher value) shaded tooth, then the outer layer must have enamel color. Enamel shade should be used as the outer layer and the

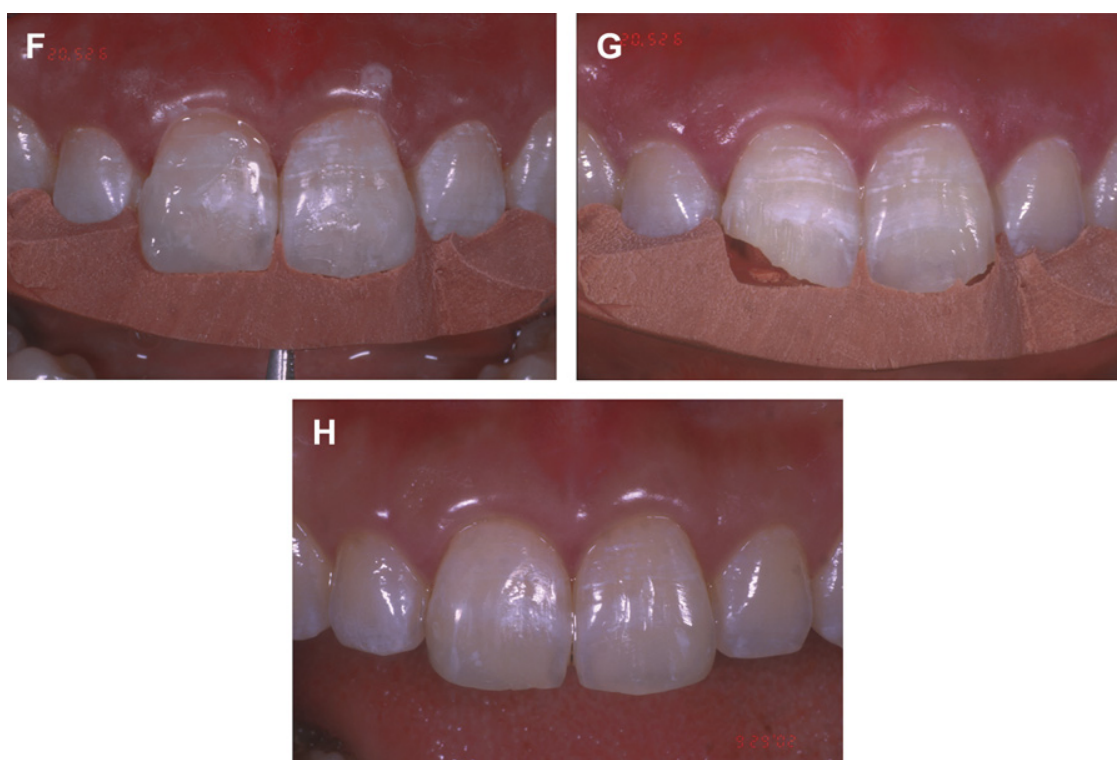


Fig. 6 (continued)

incisal shade internally. If the final outcome desired is a tooth with lower value, then the outer layer is the translucent shade, which on top of the last enamel shade acts as a transparent filtering layer resulting in a lower value.

As the complexity of the layering technique occurs, it is important to evaluate each layer from the incisal view and sagittal view. The clinician needs to be aware if they are in the dentin substitute zone or enamel substitute zone. If the various layers are added too thick, all additional layers are too far facial and removed in the contour and finishing phase.

Seamless margins

The purpose of composite layering is to establish the dentin layer and dentinal lobes in a tooth and create the wonderful nuances of enamel and enamel effects that transform into incisal translucency and incisal halo effects. If these layers have voids or are not seamless, breakdown of the restoration or the tooth restoration interface is detected early. Listed are multiple steps that must be followed to create undetectable margins [7,20,28,29]:

1. Place a proper bevel.
 - a. Facially on enamel: 2-mm knife-edge type. An additional starburst bevel with varying depths and lengths is an added benefit. These multiple bevels extend from the cavosurface margin outward, some remaining only in enamel and others depths involving dentin (Fig. 7).

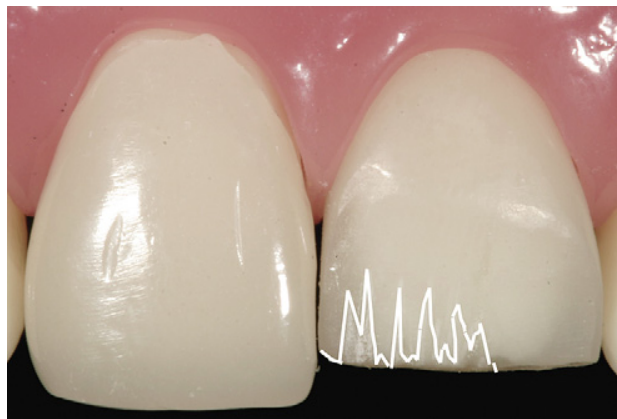

Fig. 7. Typical 2 mm long knife-edge bevel from mesial to distal; white line shows variability in depth and length of starburst design on mesial half of incisal edge. (Courtesy of Brian LeSage, DDS, Beverly Hills, CA.)

- b. Facially on dentin: no bevel, butt margin.
 - c. Lingually on enamel: chamfer margin preferably not in the contact zone.
2. Etch past the end of the bevel. By etching past the enamel bevel, the clinician is able to finish the composite to infinity slightly past the end of the bevel. This technique makes for a disappearing margin and allows for further longevity of the restoration because future polishing becomes necessary in the maintenance phase.
3. Roll the outer layer with clean gloved hands for sculptability and to prevent inclusions or voids. Once the convenience form of the desired shade of material is removed from the composite container, it has a cut or white chalky nature to the edge. If used right out of the container this zone may show up as a void in the final restoration. By taking the allocated amount of material and rolling it in clean gloved hands one can accomplish two important roles: the material is warmed slightly and is now in a better sculptable state, and the cut portion is not detectable because it is one uniform mass.
4. Sculpt the outer layer and get the geometric outline form, transition line angles, and primary anatomy to approximately 85% before curing. This can involve leaving the interproximal matrix (Mylar plastic strips; Composit-Tight metal matrix, Garrison Dental Solutions; Palodent metal matrix, Dentsply/Caulk) in place or removing it by pulling toward the lingual and using composite instruments and brushes to contour before light curing.
5. Super cure the composite and wait 10 minutes before finishing. Because composites cannot be overcured and the conversion is never 100%, it is best to super cure to maximize the physical properties of the material. The material continues to cure even after the light is removed; give the material time to relax before finishing.
6. Finish the margin back to between the etch and the end of the bevel. As described in step 1, the composite should be finished out to infinity. By

ending this margin slightly past the bevel, as the margins pick up stain over time there is a very thin zone of material that still remains polishable and easy to maintain.

7. Rotate finishing armamentarium from restoration to tooth. When using rubber or silicone finishing discs embedded with silicon carbide, aluminum oxide (degrees of grit) to prevent the grit from embedding in the margin, have the disc spinning from restoration to tooth.
8. Do not use rubber on the margins. Many manufacturers have excellent rubber polishing systems. These are best used in the body of the restoration and not at the margins because the rubber shavings can get embedded in the margin.
9. High polish appropriate for the natural dentition. An appropriate polish and luster is the key that maintains itself for the long-term (see section on polish and finishing).

Customization

Overview

In the composite mirroring layering technique, the ultimate result was obtained by using four to five different shaded or translucent materials with a very particular objective in mind. Tints were also mentioned, but the technique or application is now described.

There are five easily learned techniques to mirror the natural dentition in check lines, spots, craze lines, and any other maverick color issues seen in nature. It must be noted that tints are very strong, and while performing the layering technique many times the tints tend to disappear. They reappear as the polishing sequence progresses. Tints must never be placed on the surface, because finishing and polishing lead to their removal. Tints can be mixed to create a unique, desired color. The five techniques to creating a natural craze line are as follows:

1. Paint and thin: Using a thin paintbrush with the desired tint, usually white or brown, place the tint to mirror the adjacent tooth. The tint is on the tooth but way too wide and so thin the material from both sides leaves a thin, nonstraight line. Then light cure.
2. Scar and paint: Scar or scribe the tooth with a thin metal disc (VisionFlex, Brasseler, Savannah, Georgia) or diamond bur. Paint the desired colored tint in the scribed area and clean the excess. Then light cure (Fig. 8).
3. Matrix: After placing the second-to-most outer layer and before curing, place a Mylar or metal matrix into the composite, preferably nonstraight, and light cure. Remove the matrix, paint the desired colored tint in the grooved area, and clean the excess. Then light cure.
4. Vertical wall for depth: While placing the second-to-most outer layer create a wall in the composite, preferably nonstraight, and light cure.

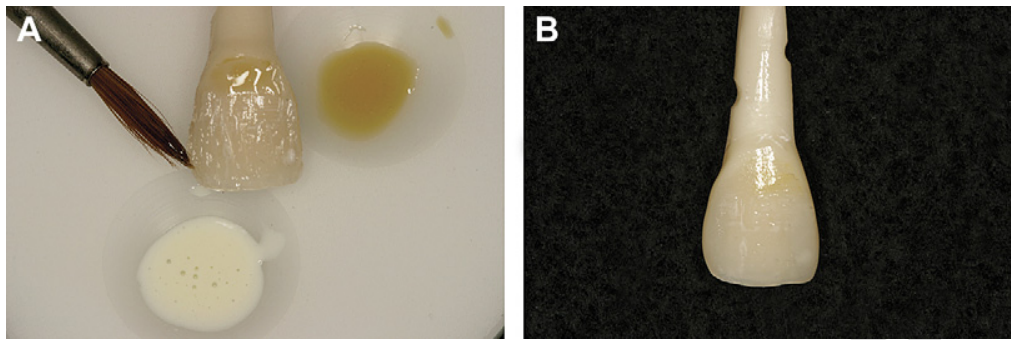


Fig. 8. (A) Tint application internally showing lines and dot maverick colors in second-to-last layer. (B) The final restoration. (Courtesy of Brian LeSage, DDS, Beverly Hills, CA.)

Paint the desired colored tint on the walled area and clean the excess. Then light cure.

5. Anneal material over the tint: While placing the most outer enamel or dentin layer create a notch or groove in the composite, preferably non-straight. Paint the desired colored tint in the notched or grooved area and anneal the composite toward and within itself, preferably in a non-straight pattern. Then light cure.

These techniques are best to learn on extracted teeth or typodont teeth, where the skills can be perfected in a nonclinical setting. Habituation is needed to master any new technique.

Finishing and polishing

This is considered by many to be the most difficult phase of anterior composite restorations. If the clinician follows the described guidelines of this article, this step becomes routine and not one to be feared. Finishing and polishing is crucial in finalizing the composite restoration to mimic nature in form, function, and longevity [30].

There is no shortcut in fabricating life-like restorations. Properly finished and polished composites allow for a proper seal of the restoration, which influences its durability and allows for minimal stain accumulation, less plaque accumulation, and better wear resistance and marginal integrity [28,29,31,32]. The finishing sequence includes diamond burs, followed by polishing discs or rubber polishing discs, points, wheels, and polishing with buffing wheels and polishing paste.

Diamond burs, specifically submicron diamonds of 50 μm or less UCLA LeSage Anterior Preparation Bur System (Brasseler USA, Savannah, Georgia), run with copious amounts of water are used to create and modify the restoration to the proper geometric outline form and contours, including the proper line angles and primary and some secondary anatomy [33]. As seen in Fig. 9, blue articulating paper can help guide the clinician through this process. In conjunction, course and fine polishing disc (KerrHawe, Kerr,

Orange, CA; EP Polishers, Brasseler, Savannah, GA; Sof-Flex Disc, 3M, St. Paul, MN; Flexi-discs, Cosmodent, Chicago, IL) run with copious amounts of water can be used to get to hard-to-reach areas to refine the aforementioned anatomic landmarks. Many times the loss of secondary anatomy is seen after this step. With the aid of electric handpieces (Ti-Max NL 400, NSK, Brasseler, Savannah, Georgia) and diamond burs, the clinician can re-establish the primary and secondary anatomy. One should check for stable centric stops and appropriate anterior disclusion. The finishing phase is not complete until interproximally and gingivally no overhangs remain and the geometric outline form is complete.

Gingivally, the use of hand instrumentation may be more ideal to remove flashing or potential overhanging material. Bard-Parker #12 or #15 blades are probably most popular, but carbide composite carvers are considered equally effective. The carbide carvers (Brasseler, Savannah, Georgia) come in several shapes matching closely to the gingival area of intended use.

Interproximally, the use of metal finishing strip (VisionFlex Strips, Brasseler, Savannah, GA, GC International Metal Strips, GC America, Alsip, IL) will initiate the bulk reduction. To make appropriate embrasures, the use of an interproximal diamond disc is needed. Embrasures need to be defined by depth and volume, and the best way to accomplish this is with thin diamond discs (VisionFlex Disc, Brasseler, Savannah, Georgia) on a straight or contra-angle. Completing the finishing and polishing of the interproximal and transition zones is crucial, because these areas are more prone to stain and plaque accumulation. The use of plastic interproximal strips (Sof-Lex Strips, 3M, St. Paul, MN; Vivadent Strips, Vident, Brea, CA) of two grits is essential to attain the ideal polished surface in this stain-susceptible zone.

Texture creation is the tertiary anatomy that makes an average composite restoration become life-like. Several possible techniques to consider are

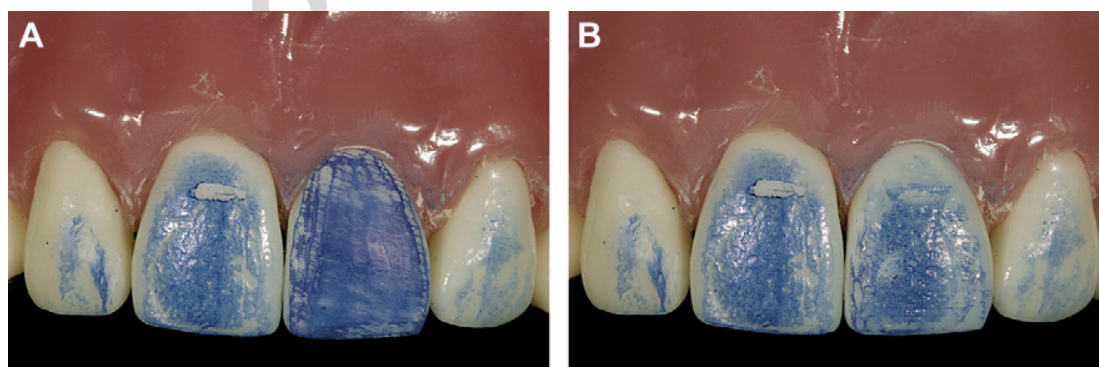


Fig. 9. Technique showing the use of articulating paper to mirror primary and secondary anatomy. (A) Once primary anatomy is close, smudge articulating paper across entire surface of tooth; note flatness and no facial anatomy or texture in facial veneer restoration on tooth #9. (B) Articulating paper confirming primary, secondary, and tertiary anatomy in direct composite restoration mirroring that of adjacent tooth #8. (Courtesy of Brian LeSage, DDS, Beverly Hills, CA.)

tapping or dragging a coarse or medium diamond bur or disc with an air or electric handpiece, using the corner or side of a cross-cut fissure bur, or using a white or green stone with various motions. This completes the finishing phase. All that is left is to establish the appropriate polish and luster.

To obtain the appropriate high polish the use of chammy-type buffing wheels and discs (Flex-Buff Disc, Cosmedent; Chammy wheel, Brasseler, Savannah, Georgia) on contra-angle and straight slow-speed handpiece is required. The use of a polishing paste (Luster Paste, Kerr, Orange, CA; Enamelize, Cosmodent, Chicago, IL; Truluster, Brasseler, Savannah, GA; or Prisma-Gloss, Dentsply/Caulk, Milford, DE) wet then dry will add gloss to the final restoration.

Created is a composite restoration that not only mimics the beauty of dentin and enamel, but also defies detection. There are still two remaining steps to consider. The first is to clean, etch, rinse, and place a seal or glaze (BisCover LV, Bisco) on the restoration to seal any microcracks or micro-surface defects from staining. The second is to take photos for self-evaluation and return of the patient with in 5 days (prescheduled) to make any alterations detected in the photography and modify any occlusal contacts, especially in anterior guidance movements.

Summary

Taking a systematic approach to direct composite restorations can greatly enhance the outcome of this multifaceted discipline. To enjoy the true art and science of cosmetic dentistry, the clinician must have a thorough understanding of tooth morphology and topography; tooth shade analysis; composite systems and layering techniques; and the use of tints, opaquers, and maverick colors and zones to create restorations that mimic nature. Once the diseased, missing, or unsightly tooth structure has the exquisite beauty of enamel and dentin in depth of color, contour, and light reflection, the finishing and polishing creates the illusion of reality. Factor in occlusion and maintenance, and direct composite restorations are the most unique and conservative restorations mirroring the reality of a tooth.

References

- [1] Lee SM. Preface. Dictionary of composite materials technology. Lancaster (PA): Technic Publishing Company; 1989.
- [2] Albers HF. Tooth colored restorations: principles and techniques. 9th edition. BC Decker Publishing; 2002.
- [3] Craig R, Powers J. Restorative dental materials. Chapter 9. 11th edition. Mosby; 2002.
- [4] Suh B. Update on adhesive dentistry. Presented at International Adhesive Symposium. Schaumburg (IL): Bisco, February 2007.
- [5] Terry D. Application of nanotechnology. Editorial Commentary, Pract Periodontics Aesthet Dent 2004;16(3):220–2.

- [6] Leinfelder KF, Sluder TB, Sockwell CL, et al. Clinical evaluation of composite resins as anterior and posterior restorative materials. *J Prosthet Dent* 1975;33(4):407–16.
- [7] Eubank J, LeSage B. Presented at the UCLA aesthetic continuum, composite lecture and hands-on workshops, 1997–2006. UCLA Dental School, Los Angeles.
- [8] O'Brien WJ, editor. *Dental materials and their selection*. 3rd edition. Carol Stream (IL): Quintessence Publishing Co; 2002. p. 114–6.
- [9] Mitra S, Wu D, Holmes B. An application of nanotechnology in advanced dental material. *J Am Dent Assoc* 2003;134(10):1382–90.
- [10] Sidaway I. *Color mixing bible*. NY: Watson-Guptill Publication; 2002.
- [11] Dietschi D. Free-hand composite resin restorations: a key to anterior aesthetics. *Pract Periodontics Aesthet Dent* 1995;7(7):15–27.
- [12] Dietschi D, Dietschi JM. Current developments in composite materials and techniques. *Pract Periodontics Aesthet Dent* 1996;8:603–14.
- [13] Dietschi D. Free-hand bonding in the esthetic treatment of anterior teeth: creating the illusion. *J Esthet Dent* 1997;9(4):156–64.
- [14] Dietschi D, Ardu S, Krejci I. Exploring the layering concepts for anterior teeth. In: Rouley JF, Degrange M, editors. *Adhesion: the silent revolution in dentistry*. Chicago: Quintessence; 2000. p. 235–51.
- [15] Chiche G, Pinault A. *Aesthetic of anterior fixed prosthodontics*. Chicago: Quintessence; 1994.
- [16] Dietschi D. Layering concepts in anterior composite restorations. *J Adhes Dent* 2001;3:71–80.
- [17] Gordon AA, vonderLehr WN, Herrin HK. Bond strength of composite to composite and bond strength of composite to glass ionomer lining cements. *Gen Dent* 1986;34:290–3.
- [18] Terry D, Leinfelder K. An integration of composite resin with natural tooth structure: the CL IV restoration. *Pract Proced Aesthet Dent* 2004;16(3):235–42.
- [19] Miller M. *Reality: the information source for esthetic dentistry*. Houston (TX): Reality Publishing; 2006.
- [20] Fahl NJ. Predictable aesthetic reconstruction of fractured anterior teeth with composite resins: a case report. *Pract Periodontics Aesthet Dent* 1996;8(1):17–30.
- [21] Devoto W. Clinical procedure for producing aesthetic stratified composite resin restorations. *Pract Proced Aesthet Dent* 2002;14(7):541–3.
- [22] Sproul RC. Color matching in dentistry. Part 1. The three-dimensional nature of color. *J Prosthet Dent* 2001;86:453–7.
- [23] Hall NR, Kafalias MC. Composite colour matching: the development and evaluation of a restorative colour matching system. *Aust Prosthodont J* 1991;5:47–52.
- [24] Vanini L. Light and color in anterior composite restorations. *Pract Periodontics Aesthet Dent* 1996;8(7):673–82.
- [25] Deliperi S, Bardwell DN, Congiu MD. Reconstruction of severely damaged endodontically treated and bleached teeth using a microhybrid composite resin: two-year case report. *Pract Proced Aesthet Dent* 2003;15(3):221–6.
- [26] Vanini L, Mangani FM. Determination and communication of color using the five color dimensions of teeth. *Pract Proced Aesthet Dent* 2001;13(1):19–26.
- [27] Behle C. Placement of direct composite veneers utilizing a silicone build-up guide and intraoral mock-up. *Pract Periodontics Aesthet Dent* 2001;12(3):259–66.
- [28] Jefferies SR, Barkmerier WW, Gwinnett AJ. Three composite finishing systems: a multisite in vitro evaluation. *J Esthet Dent* 1992;4(6):181–5.
- [29] Goldstein RE. Finishing of composite and laminates. *Dent Clin North Am* 1999;33(2):305–18.
- [30] Miller M. Contouring and polishing resin-based materials. *Reality; the techniques*. 2003;1:23–29.

- [31] Powers JM, Fan PL, Raptis CN. Color stability of new composite restorative materials under accelerated aging. *J Dent Res* 1980;59(12):2071–4.
- [32] Sarac D, Sarac SY, Kulunk S. The effects of polishing techniques on the surface roughness and color change of composite resins. *J Prosthet Dent* 2006;96:33–40.
- [33] Blitz N. *Diagnosis and treatment evaluation in cosmetic dentistry: a guide to accreditation criteria*. American Academy of Cosmetic Dentistry; Madison (WI).

Author's personal copy