

# Composites in a Three-Dimensional World

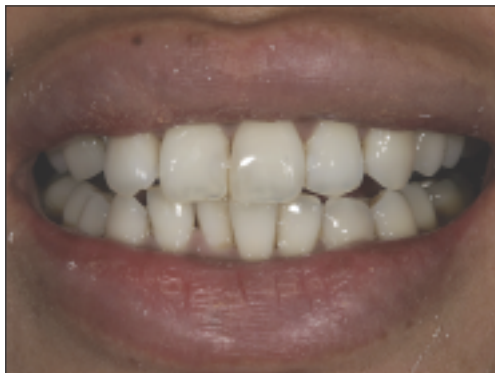

Brian LeSage,  
DDS

## INTRODUCTION

Composite resins have evolved to offer vast improvements over previous generations and are considered among the most versatile cosmetic restorative material available.<sup>1-3</sup> Through advancements in material sciences and layering techniques, composites now demonstrate improved strength, handling characteristics, durability, and lower polymerization shrinkage rates to provide dentists with greater ease of use and predictability when placing restorations intraorally.<sup>1-3</sup> Available in a variety of shade options that can be polished to a natural luster, today's composites enable creation of restorations that seamlessly mimic surrounding dentition for unmatched aesthetic.<sup>1-3</sup>

In addition to these advantageous characteristics, composite restorations are minimally invasive and allow greater preservation of sound tooth structure.<sup>1-3</sup> Although required in some indications, aggressive



**Figure 1.** Prior to orthodontic treatment, the patient presented with unaesthetic dentition that demonstrated crowding, rotations, overlapping, and lingualized tooth No. 6, which lacked proper buccal reveal.

Embracing such an approach provides the unique opportunity to create lifelike restorations that serve patients for an extended period of time.<sup>6-8</sup>

Additionally, incorporating techniques that promote predictable outcomes facilitates success. To create a seamless restoration, a starburst bevel of 2.0+ mm is recommended, except on the gingival margin if dentin is exposed.<sup>1</sup> Further, vinyl polysiloxane (VPS) matrices can be used as adjuncts to provide placement limits in terms of com-

posite material volume 3-dimensionally and help maintain proper incisal length and edge thickness.<sup>1</sup> Then, when layering composite, it will be incumbent upon the dentist to ensure no air voids are present in the increments; placing smaller increments predictably, rather than bulk quantities of material, helps to control the material.<sup>1</sup> Further, this technique enables the dentist to replicate the polychromicity, depth of color, and translucency required for natural aesthetic and harmony with the surrounding dentition.<sup>1</sup> Finally, proper finishing and polishing techniques appropriate to the restoration and type of composite placed should be incorporated into the restorative process.<sup>1</sup>

## NANOHYBRID COMPOSITES

Consisting of nanomer and nanocluster agglomerate fillers, restorations placed with nanohybrid composites appear layered and polychromatic, while demonstrating the

appropriate opacity, multitranslucency, and incisal halo where indicated.<sup>5-7</sup> Offering color adaptability, restorations completed with nanohybrid composites such as Venus Diamond (Heraeus Kulzer) allow dentists to use single or multiple shades of layered material to reproduce the natural appearance of the patient's dentition.<sup>5-8</sup>

Offering greater ease of use than prior generations of composites, the improved sculptability and flowability of nanohybrid composites also enable dentists to shape and contour restorations quickly and efficiently.<sup>6-8</sup> Allowing dentists to bring restorations to full contour before premature curing occurs, dentists have experienced greater success rates when placing direct nanohybrid composite restorations.<sup>6-8</sup>

The size of the filler particles, like those present in Venus Diamond, offer enhanced resistance to wear from masticatory forces, contributing to the success of nanohybrid composites and enabling their use in both the anterior and posterior.<sup>6-9</sup> Further, nanohybrid composites demonstrate lower polymerization shrinkage rates, which reduces the risk of marginal leakage, the formation of secondary caries, and the possibility of restorative failure.<sup>6-8</sup>

## CAD/CAM TECHNIQUE AND MATERIALS

Historically, direct restorative techniques presented various clinical challenges that were difficult to overcome.<sup>10,11</sup> Concerned with isolation, contamination, and individual patient characteristics, many dentists struggled to gain predictability in their restorative protocol.<sup>10,11</sup> Additionally, direct layering techniques using non-homogenous materials decreased the strength and durability of the direct composite restoration, often making them prone to clinical failure.<sup>10,11</sup>

Offering a solution to these clinical challenges, today's advanced computer-aided design and manufacture (CAD/CAM) systems enable dentists and technicians to create strong and highly aesthetic all-ceramic inlays, onlays, partial and full-crowns, veneers, and 4-unit bridges.<sup>10,11</sup> CAD/CAM armamentarium recently has expanded with the development of composite blocks (Z100 [3M ESPE]) that can be milled with

*continued on page 108*

---

*...proper finishing and polishing techniques appropriate to the restoration and type of composite placed should be incorporated....*

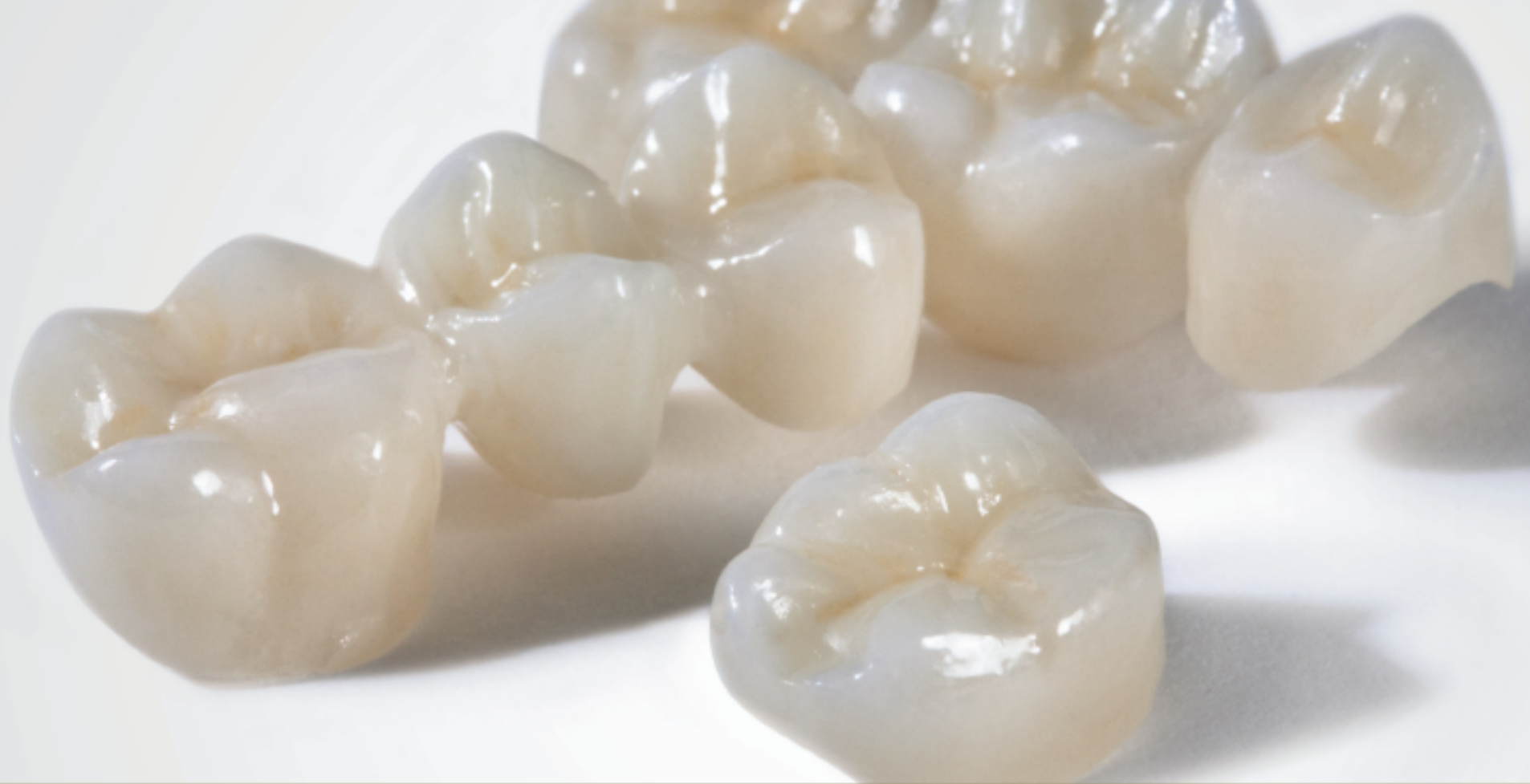---

removal of sound tooth structure has been directly related to greater incidences of clinical challenges, including gingival irritations and the need for root canals.<sup>4,5</sup> Minimally invasive and highly conservative, recent increases in composite use have coincided with the current shift toward comprehensive care and interdisciplinary treatment philosophies in the dental industry.<sup>6-8</sup>

Combined with concepts from aesthetic dentistry and prosthodontics, the comprehensive care model focuses on thoroughly understanding function, minimally invasive dentistry, and adhesive dentistry, with an emphasis on aesthetics.<sup>6-8</sup> Foregoing reparative concepts of the past, today's innovative materials and techniques allow dentists to improve function and aesthetic without aggressive tooth structure removal.<sup>6-8</sup> Aesthetics are comprehensively achieved by blending facial and tooth characteristics with function and durability.<sup>6-8</sup>

# Zirconia evolved.

UNCOMPROMISING ESTHETICS. OUTSTANDING STRENGTH. FLAWLESS FIT.



INTRODUCING THE ALL-NEW KDZ BRUXER.  
THE **BEST** FULL-CONTOUR ZIRCONIA SOLUTION AVAILABLE.  
EXCLUSIVELY FROM KEATING DENTAL ARTS.

The all-new KDZ Bruxer is so precise and predictable you can prep and rest assured that the job is done the first time, every time. Precision-milled and finished by hand, it fits and functions flawlessly.

"BEST LOOKING  
solid zirconia crown out there. The KDZ  
Bruxer is not just better than gold, these  
are better looking than some crowns I've  
received from other labs."

Dr. Roy Davis, Nantucket, MA

CALL OR CLICK TODAY  
**888-407-6571**  
keatingdentalarts.com

#### THE KDZ BRUXER:

- Replaces full-cast gold
- Is perfect for posterior bridges
- Is the esthetic choice



**FREE** ADJUSTMENT &  
POLISHING KIT  
A \$60 value with your first KDZ Bruxer case\*



Come See Us In New York! • November 27-30, 2011 • Booth #821

\* Offer cannot be combined with any other offer or promotion. Free adjustment kit available with first KDZ Bruxer case only.

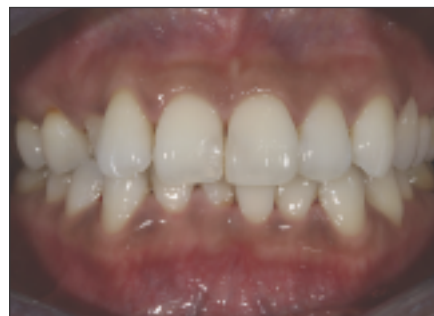**FREE** info, circle 70 on card



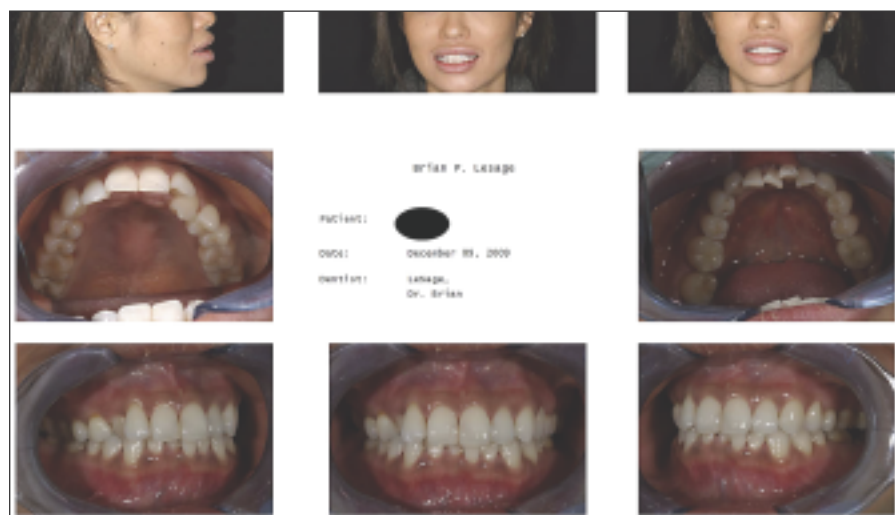### Composites in a Three-Dimensional...

continued from page 106

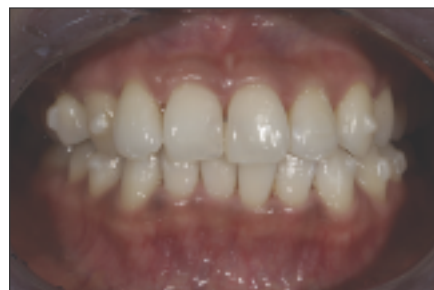CAD/CAM technologies, like the CEREC AC system (Sirona Dental Systems),<sup>9,10</sup> Increasing predictability, CAD/CAM technologies have



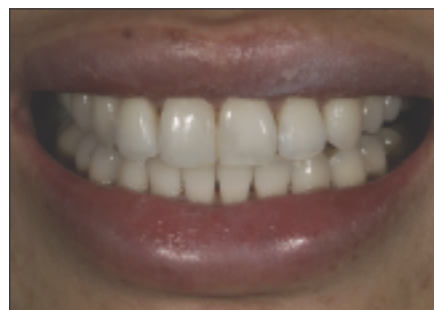**Figure 2.** A retracted view of the patient's dentition prior to orthodontic treatment with aligner trays (Invisalign [Align Technology]).



**Figure 3.** Multiple photographs of the patient's functional and aesthetic issues were taken for Invisalign submission.



**Figure 4.** After phase 1 of Invisalign treatment, another series of photographs were taken to submit for Invisalign refinement submission.



**Figure 5.** Upon completion of orthodontic treatment, the patient was still unhappy with the appearance of tooth No. 6, which had less buccal reveal than tooth No. 11. At this time in treatment, a direct composite veneer had been placed on tooth No. 8.

enabled dentists to provide patients with restorations that are exceptionally strong and demonstrate the durability required to withstand mastication forces.<sup>10,11</sup>

Allowing efficient and timely completion of even complex restorative cases, CAD/CAM users also have experienced increased patient acceptance, since the dentist can scan the teeth and soft tissues, refine the design in 3 dimensions, and mill the restoration in-office and in a single appointment.<sup>10-12</sup> According to Christensen,<sup>11</sup> "Patients appreciate the convenience of having restorations placed in one appointment, instead of having to come back for a second seating appointment."

Although CAD/CAM technologies offer many advantageous features

over conventional laboratory or in-office freehand techniques—such as the fact that homogenous materials have minimal processing errors and contaminants and therefore have better strength and durability<sup>13</sup>—milled restorations many times lack proper aesthetic and appear monochromatic. To improve the polychromicity and overall aesthetic of indirect or direct-indirect CAD/CAM restorations, the author has developed a simple but effective postmilling layering technique that utilizes a highly aesthetic nanohybrid composite material and subtle characterization tints to create a naturally appearing restoration that harmoniously mimics the surrounding dentition within the oral cavity.

### CASE REPORT

#### Diagnosis and Treatment Planning

A 37-year-old female presented with malocclusion involving a cross-bite and severe crowding in the lower anterior dentition (Figures 1 and 2). She was not pleased with the appearance of her smile and desired partial

*...milled restorations many times lack proper aesthetic and appear monochromatic.*

to full-mouth reconstruction with veneers to improve aesthetics.

Although this treatment would have been effective with a minimum of 6 to 8 of the upper/lower anterior teeth, in her case, preparation for veneers would have required significant removal of otherwise sound tooth structure. Leading to greater incidences of future clinical challenges and failures, the loss of sound tooth structure has been related to increased need for root canals and gingival irritations. The patient was informed that veneers have a clinical expectancy ranging from 10 to 15 years before issues like chipping, fracture, and discoloration indicate the need for replacement. Requiring a lifetime commitment, the patient and dentist decided veneers were not the best treatment option.

Further discussion revealed she was seeking perfection in her smile with a timely and highly aesthetic solution. She was informed that perfection may not be achieved if the underlying crowding, malocclusion, and cross-bite were not addressed first. Therefore, a multidisciplinary treatment plan based on a comprehensive care and aesthetic philosophy was agreed upon to provide the greatest benefit. The final treatment plan included orthodontics, followed by the author's innovative new concept of using a no preparation CAD/CAM milled and layered composite veneer.

#### Before Restorative Treatment Began

Prior to any restorative work, orthodontic therapy with removable aligner trays (Invisalign [Align Technology]) was utilized to correct the cross-bite, malocclusion, and crowding in the mandibular arch. Initially, all necessary diagnostic information, including a proper series of photographs, were analyzed and reviewed with the patient before being sent to Invisalign for fabrication (Figure 3). Once complete, the aligner trays were delivered and the patient began phase 1 of treatment.

Upon completion of phase 1 orthodontic treatment, the patient returned to the office for further evaluation. After only one treatment phase, the lower arch crowding was significantly reduced, and tooth No. 6 "jumped" the arch. However, perfection for this

patient was not achieved, since tooth No. 6 remained slightly tucked behind tooth No. 7. Although pleased with the initial results, the patient was still concerned with the rotation of some of her teeth, and the dentition still violated some aesthetic parameters. Therefore, VPS impressions (Flexitime [Heraeus Kulzer]), a new series of photographs, and a bite registration (Flexi-Bite [Heraeus Kulzer]) were taken and sent to Invisalign for refinement treatment (Figure 4).

Upon completion of the refining stage of treatment, tooth No. 6 was in a better position and function was greatly improved. However, the dentition still violated some aesthetic parameters, and the patient disliked the remaining cervical/gingival black triangles. Willing to compromise temporarily with the appearance of the interproximal spaces, the patient remained concerned with the lack of buccal profile of tooth No. 6 compared to tooth No. 11 (Figure 5). However, it was in the proper position to provide canine guidance and therefore immediate disclusion.

Although tooth No. 6 could have been brought more buccally, doing so would have violated canine guidance and caused the loss of immediate disclusion in right working movement. Therefore, the treatment of choice was the following innovative no/minimal preparation CAD/CAM milled composite veneer layered with a highly aesthetic nanohybrid composite.

#### Clinical Protocol

The shade of tooth No. 6 was initially predetermined using the 3D Master Shade Guide (Vident). To ensure a life-like result, a spectrophotometer (EZ-Shade [Vident]) was then utilized, and the shade was confirmed and determined to be A1 from the VITA Classic Shade Guide (Vident), or 1M1 to 1M2 on the 3D Master Guide.

After determining the proper shade of composite that would be required to create a naturally-appearing restoration, a coarse diamond (Brasseler USA) was used to remove aprismatic enamel and a small amount of attachment that remained on tooth No. 6 from orthodontic (Invisalign) treatment (Figure 6). Once prepared (Figure 7), full-impressions were taken with a VPS material (Flexitime). The

continued on page 110

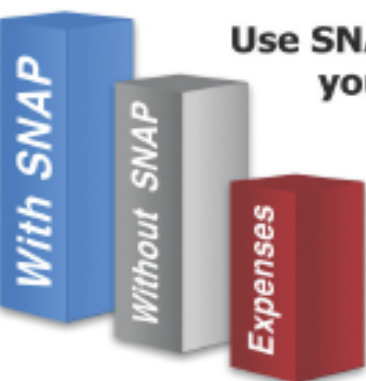

# Increase Chairside Production Now!

Use **SNAP** to turn non-cosmetic patients into cosmetic patients

In **LESS THAN A MINUTE**, SNAP Imaging Software easily simulates whitening, veneers, replacing missing teeth with bridges or implants, perio surgery and much more.

Give a **FREE "Smile Evaluation Photo"** to Everyone that Walks in the Door!



Use **SNAP** daily and watch your profits soar!

Note that as soon as the operating expenses are covered by your normal caseload, any increase in revenue **DRAMATICALLY** increases your overall profits.



**A Cosmetic Simulation for Susan**  
Cosmetic Dentistry by Dr. John Smith at 812-555-7...

The above picture(s) are a simulation of the potential outcome of cosmetic dental procedures, your




**Actual Non-Simulated After Photo**

"After seeing my dental simulation photo, I wanted to be able to smile again!"  
~ Susan G., Orlando, Florida

**Unconditional 30-Day Money Back Guarantee,** if your cosmetic revenue does not increase immediately.



**SNAP** cosmetic dental simulation software works with **ANY** camera and **ANY** printer.



**Dr. Raymond Frye, DMD**  
**Celebrity makeover dentist.**

"The first day we received **SNAP**, our monthly production went up **\$20,000.**"



**Martin Goldstein, DMD**  
**Author, lecturer.**

"**SNAP** definitely peaks interest, even from our non-cosmetic patients."



**Jacquelyn A. Stanfield, DDS**  
**VIP Dental Care.**

"We immediately saw a dramatic increase in patient acceptance of restorative and cosmetic dentistry."



866-987-7627

Visit us at: [www.SnapDental.com](http://www.SnapDental.com)

FREEinfo, circle 71 on card



### Composites in a Three-Dimensional...

*continued from page 108*

impressions were then inspected for voids and defects. Models were then poured, which would be used to indirectly fabricate a composite mock-up and the definitive restoration.

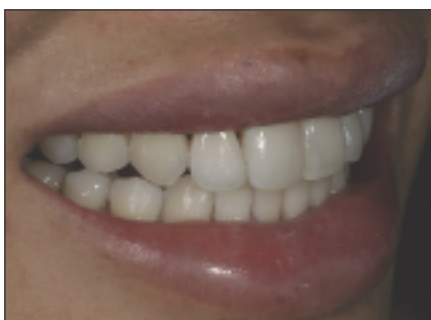Although indirect fabrication of the mock-up on the model was chosen in this case, the following technique may be used to fabricate the mock-up directly. However, the sequential steps for mocking up and scanning are slightly different. For example, the initial tooth form would first be sprayed with scanning powder and scanned intraorally. After scanning, the mock-up is then developed on the unprepared tooth and scanned. Upon completion, the mock-up would then be removed from the mouth and used as a guide during indirect fabrication of the definitive restoration.

#### Dental Laboratory Protocol

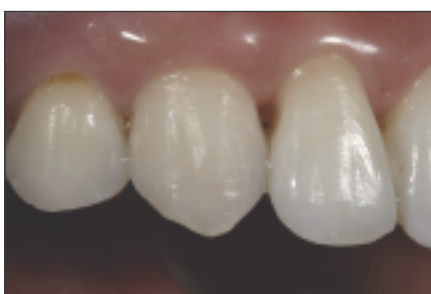To create the basis for the milled restoration and an example that could be used during final buildup, a mock-up of tooth No. 6 was fabricated from nanohybrid composite (Venus Diamond) in shade A1 on the model. Initially, the composite was layered onto the facial surface on the model of tooth No. 6 and slightly over contoured to the facial and gingival aspects to meet CEREC system thickness requirements. After light-curing, additional layers of A1 composite were added to improve contour and increase bulk for scanning. The additional layers of composite were then light-cured.

To prepare the mock-up for scanning and milling, a flamed shaped diamond bur (8863-012 [Brasseler USA]) was used to establish the mesial line angle and slightly mirror tooth No. 11, while also providing harmony and balance. Once the initial contours were established, the mock-up was lightly polished to improve the outline form, incisal-edge, and line angles.


Scanning powder (Opti-Spray [Sirona Dental Systems]) was then sprayed on the mock-up of tooth No. 6 on the model. Utilizing a CAD/CAM system (CEREC), the mock-up of tooth No. 6 was left on the model and scanned. To capture the no preparation tooth form, the mock-up was removed from the model and scanning powder was applied. Once the tooth form had been scanned, the CEREC software was placed in correlation mode, and the restoration was fully designed and milled from a CAD/CAM composite block (Z100) (Figure 8).



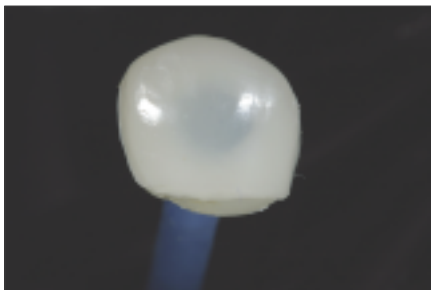**Figure 6.** Right side smile view of the patient after Invisalign.



**Figure 7.** Tooth No. 6 underwent minimal preparation with a coarse diamond bur to remove aprismatic enamel.



**Figure 8.** A photograph of the Z100 block (3M ESPE) after milling with CEREC (Sirona Dental Systems).



**Figure 9.** The composite layered veneer demonstrated high polish on the jig.

#### Jig Fabrication

After milling, a coarse diamond wheel was used to remove remaining “wings” from the composite block (Z100) to improve access to the sprue. The restoration was then cut, not snapped, from the sprue utilizing the coarse diamond wheel. The sprue was then cut from the restoration, except for a small portion that would aid in custom jig fabrication. Created in the laboratory prior to layering, the custom jig allows the dentist/technician to protect the margins of the restoration and aids in cutback, layering, and finishing/polishing phases.

Initially, the internal surfaces of the veneer were checked for contaminants from the CEREC milling pro-

cess, which utilizes oil in water. After drying the internal surfaces to remove contaminants and improve retention, the lingual veneer surface was placed on the end of a stick'em (MicroStix [Micro Brush]) and held facially down on the bench. Petroleum jelly (Vaseline) was then placed on the inner surface of the restoration and thinned. Critical to the success of the jig, the intaglio surface of the restoration should appear slightly glossy from the petroleum jelly (Vaseline).

After air-drying, silicone liquid dam material (Liquidam [Discus Dental]) was placed on the lingual surface over the petroleum jelly. The material was allowed to flow to the margins of the veneer and light-cured. This layer was left bulky to allow the clinician/technician to clearly see where the restoration ended and the jig began. Since tooth No. 6 was only minimally prepared to remove aprismatic enamel and a small amount of attachment prior to impression taking, the silicone liquid dam material

facial surface of the restoration had nearly broken through the surface of the composite. When proper depth was achieved, the blueness of the stick'em (MicroStix) and whiteness of the silicone material was visible through the restoration. Additionally, after the initial cutback, the gingival margin and incisal edge remained apparent.

#### Composite Layering

To improve the retentiveness of the composite layers and remove contaminants, total-etch one-bottle adhesive (iBond [Heraeus Kulzer]) was placed on the restoration on the jig for 30 seconds to cleanse and slightly etch the veneer. Since fabrication was being completed on the laboratory bench, there was no need to agitate the adhesive agent after application. Therefore, the material was air-thinned to evaporate the primer solvents and light-cured.

To improve sculptability, the nanohybrid composite material (Venus Diamond), in shade A1 was slightly

*The risk of damage to conventional veneers is typically low during cutback....*

was finished back to a knifelike edge circumferentially.

To provide added support, rigidity, and bulk during the layering process, the silicone rubber dam material was then covered with a flowable composite. The author typically uses any shade of expired flowable composite, since the composite is only being used to hold the veneer securely in place. The composite was placed in a similar fashion as the silicone material and light-cured. If necessary, further layers of composite could be added at this point to strengthen the jig.

Upon approval of the strength and visibility of the veneer/jig interface, a coarse diamond wheel (Dialite [Brasseler USA]) was used to smooth the surface and remove the remaining piece of sprue to ensure a clean working field.

#### Cutback

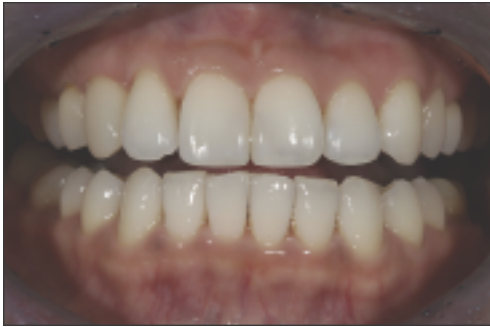The risk of damage to conventional veneers is typically low during cutback, since they typically demonstrate a thickness of 0.5 mm to one mm. However, since the veneer was only 0.3 mm to 0.5 mm thick in this case, caution was used.

Utilizing the diamond wheel (Dialite), the milled Z100 restoration was cut back and thinned until the

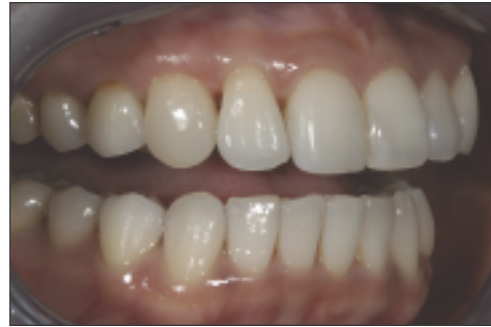warmed prior to placement on the veneer. Utilizing a modeling instrument, the composite was placed on the incisal edge of the veneer and “vibrated” into place using a series of quick pushing, pulling, and tapping movements. To further build and create the incisal edge, additional composite was added and the proper incisal edge contour was established. This initial layer was left slightly irregular and light-cured.

A low modulus microfilled composite gray tinting material (Characterization Tints [Bisco]) was then placed on the milled restoration to create a subtle but more natural appearance and then light-cured. In cases requiring extremely thin veneers, tinting materials should be used in lieu of additional layers of composite to prevent the restoration from becoming too thick.

Shade A1 composite (Venus Diamond) was slightly warmed and placed on the surface of the milled veneer. Using the modeling instrument, the material was vibrated into place with a series of quick pulling, pushing, and tapping movements. This layer was kept thin to allow room for an additional layer of composite in shade B1 (Venus Diamond) to provide greater depth of color. Once



**Figure 10.** A retracted view of the cutback Venus Diamond composite layered veneer that was fabricated using CEREC technology and a Z100 composite computer-aided design and manufacturer block.



**Figure 11.** The retracted right side view of the completed restoration, which demonstrated ideal coloring, outline form, and texture in alignment with the natural dentition.

the proper outline form was established with the A1 composite (Venus Diamond), the restoration was compared to the structure of the tooth No. 11 from the VPS impression. To create reasonable symmetry with tooth No. 11, the contour of the mesial-transition line angle should mirror No. 11, while other outline forms, including the incisal edge and the incisal plane, should demonstrate variety. After deeming the contour satisfactory, this layer of composite was light-cured.

To improve the depth of color of the restoration, B1 composite (Venus Diamond) was slightly warmed and vibrated into place over the layer of A1 composite using the pushing, pulling, and tapping method. In the B1 composite layer, it was beneficial to begin building the primary anatomy and appropriate outline form to create harmony and balance with the surrounding dentition. Although the final layer of composite, the restoration surface was made smooth, but not perfectly. The B1 layer of composite was then light-cured.

#### Finishing and Polishing

Utilizing a pink diamond wheel (Dialite), the restoration was segmented into mesial and distal planes to create a slight ridge down the center of the restoration. The prominent mesial ridge and the distal plane were then reduced to create the “tucked-in” appearance. During this reduction, most of the B1 composite material was removed from the distal plane. To increase visibility of the margins, the diamond wheel (Dialite) was used on a slow speed on the edges of the restoration. The incisal edge was then contoured.

To impart texture on the layered composite on the restoration surface, a round bur and electric handpiece were utilized. To prevent notches and scratches, the electric handpiece was set on speed 11 in the 1:1,000 mode. Although the speed setting used was

substantial in this case, it may be raised or lowered as needed to meet the needs of the specific case. To build secondary anatomy, the bur was allowed to “kiss” the restoration surface as it was run across 2 to 3 times to create naturally-appearing demarcation lines. The restoration was then examined, and further texture was added as needed.

To bring the composite veneer to high polish and luster, a diamond powder-filled silicone polishing system (Venus Supra [Heraeus Kulzer]) was utilized. Initially, a purple coarse polishing tip was dipped in water and run over the facial aspect to soften, blend, and smooth the round-bur textured surface. A gray fine polishing tip was then run over the facial to soften the restoration anatomy to prevent it from appearing scratched.

Diamond polishing paste (Enamelize [Cosmedent]) was then placed on a pad and thinned to prevent it from spraying on the dentist/technician and the laboratory. Utilizing a wet goat hairbrush that incorporates a chamois (Brasseler USA), pressure was applied as the polisher was moved back and forth over the restoration surface. The electric handpiece was then set on 24 in the 1:1,000 mode, and the restoration was polished with a dry goat hairbrush with chamois (Brasseler USA), slight pressure, and the diamond polishing paste (Enamelize). During polishing, care was taken to finish back to the margins and create nice tertiary anatomy.

Once completed, the thin milled and layered composite veneer demonstrated exceptional shine, anatomy, reflective surfaces, and appeared to have a natural glisten (Figure 9).

#### Clinical Preparation

Prior to preparation, the restoration was placed on the model to confirm accuracy, then tried-in the patient's mouth to confirm aesthetic, fit, and function. Upon patient approval,

tooth No. 6 was isolated by placing Teflon tape (Home Depot) around the adjacent teeth to ensure simple clean up of excess cement. A 32% phosphoric acid etchant (Uni-Etch [Bisco]) was first placed on the enamel of tooth No. 6 for 15 to 30 seconds. The etchant was then rinsed from the tooth with copious amounts of water and suction. Since etching was exclusively on the enamel, it was possible to then air-

dry the tooth.

A 3-step total-etch universal dental adhesive system (All-Bond 3 [Bisco]) was then used to prepare the tooth for final cementation. Initially, the primer was placed on the enamel of the tooth and allowed to sit for 15 to 30 seconds. A combination of suction and air was then used to evaporate the solvent (necessary contaminant) from the primer and remove excess material from the tooth surface. The primer was then light-cured to ensure the highest bond strength between the cement and tooth would be achieved. After curing, the adhesive (All-Bond 3) was placed on the prepared tooth and left uncured.

#### Definitive Seating

To ensure simple cleanup, nanohybrid composite (Venus Diamond) in the same shade used for the restoration was selected to seat the restoration. After warming, a thin ribbon was placed on the preparation. The veneer was then seated on the facial surface of tooth No. 6.

Prior to light-curing, excess composite cement was removed from the margins and interproximal spaces with a dental explorer. To provide retention for further cleanup, the veneer was then cured on the lingual. Utilizing a spoon excavator, remaining excess cement was removed from the margins and dental floss was used to remove cement from interproximal spaces. The restoration was then cured from the buccal.

Utilizing a carbide bur, the lingual was then cleaned to ensure a smooth transition for the patient and good canine guidance. The lingual was then polished with a purple-tipped diamond polisher (Venus Supra) to complete the restoration.

After completing the case, the CAD/CAM milled composite veneer (CEREC/Z100) layered with an aesthetic nanohybrid composite (Venus Diamond) was seamlessly integrated into the margin and appeared indis-

tinguishable from the surrounding dentition (Figures 10 and 11).

#### CONCLUSION

Although the restoration placed in this case could have been designed with the CEREC system, finished, polished, and seated immediately after milling, it would have lacked natural-looking aesthetics and appeared monochromatic. Similar to layered porcelain restorations, coloring and characterization in milled composite must be placed internally with multiple thin layers of composite and tints. Demonstrating exceptional depth of color and individual characteristics, restorations fabricated from flawlessly machined materials and layered with highly aesthetic composites and tints provide patients with restorations that are indistinguishable from the surrounding dentition. ♦

#### References

1. LeSage BP Aesthetic anterior composite restorations: a guide to direct placement. *Dent Clin North Am.* 2007;51:359-378,viii.
2. Sensi LG, Strassler HE, Webley W. Direct composite resins. *Inside Dentistry.* 2007;3:76.
3. Fortin D, Vargas MA. The spectrum of composites: new techniques and materials. *J Am Dent Assoc.* 2000;131(suppl):26S-30S.
4. Ritter AV. Direct resin-based composites: current recommendations for optimal clinical results. *Compend Contin Educ Dent.* 2005;26:481-482, 484-490, quiz 492,527.
5. Puckett AD, Fitchie JG, Kirk PC, et al. Direct composite restorative materials. *Dent Clin North Am.* 2007;51:659-675,vii.
6. Levin RP. What constitutes “ideal dentistry” today? *Compend Contin Educ Dent.* 2011;32:8-9.
7. Jivraj SA, Chee WW. An interdisciplinary approach to treatment planning in the esthetic zone. *J Calif Dent Assoc.* 2003;31:544-549.
8. LeSage BP. Minimally invasive dentistry: paradigm shifts in preparation design. *Pract Proced Aesthet Dent.* 2009;21:97-101; quiz 102,116.
9. Venus diamond & venus diamond flow [brochure]. South Bend, IN: Heraeus Kulzer Inc; 2010.
10. Fasbinder DJ. Restorative material options for CAD/CAM restorations. *Compend Contin Educ Dent.* 2002;23:911-924.
11. Christensen GJ. Is now the time to purchase an in-office CAD/CAM device? *J Am Dent Assoc.* 2006;137:235-238.
12. Allen KL, Schenkel AB, Estafan D. An overview of the CEREC 3D CAD/CAM system. *Gen Dent.* 2004;52:234-235.
13. McLaren E. Personal communication. UCLA Esthetic Continuum, 2002, Los Angeles, Calif.

**Dr. LeSage** graduated magna cum laude with the Omicron Kappa Upsilon Honor Dental Society award from the University of Maryland, Baltimore College of Dental Surgery in 1983. He is in private practice in Beverly Hills, Calif, emphasizing aesthetic and reconstructive dentistry. Dr. LeSage is a Fellow of the American Academy of Cosmetic Dentistry (AACD) and was appointed as a consultant and examiner for the AACD accreditation process, and he is the Fellowship Chair. He is also a Fellow with the AGD. He is the founder and director of the University of California, Los Angeles, aesthetic continuum levels I and II. Dr. LeSage is also the director and founder of the Beverly Hills Institute of Dental Aesthetics and an ADA seminar series speaker. He can be reached at brian@cosmetic-dentistry.com.

*Disclosure:* Dr. LeSage received an honorarium from Heraeus Kulzer for demonstrating the use of specific products in this case presentation.